

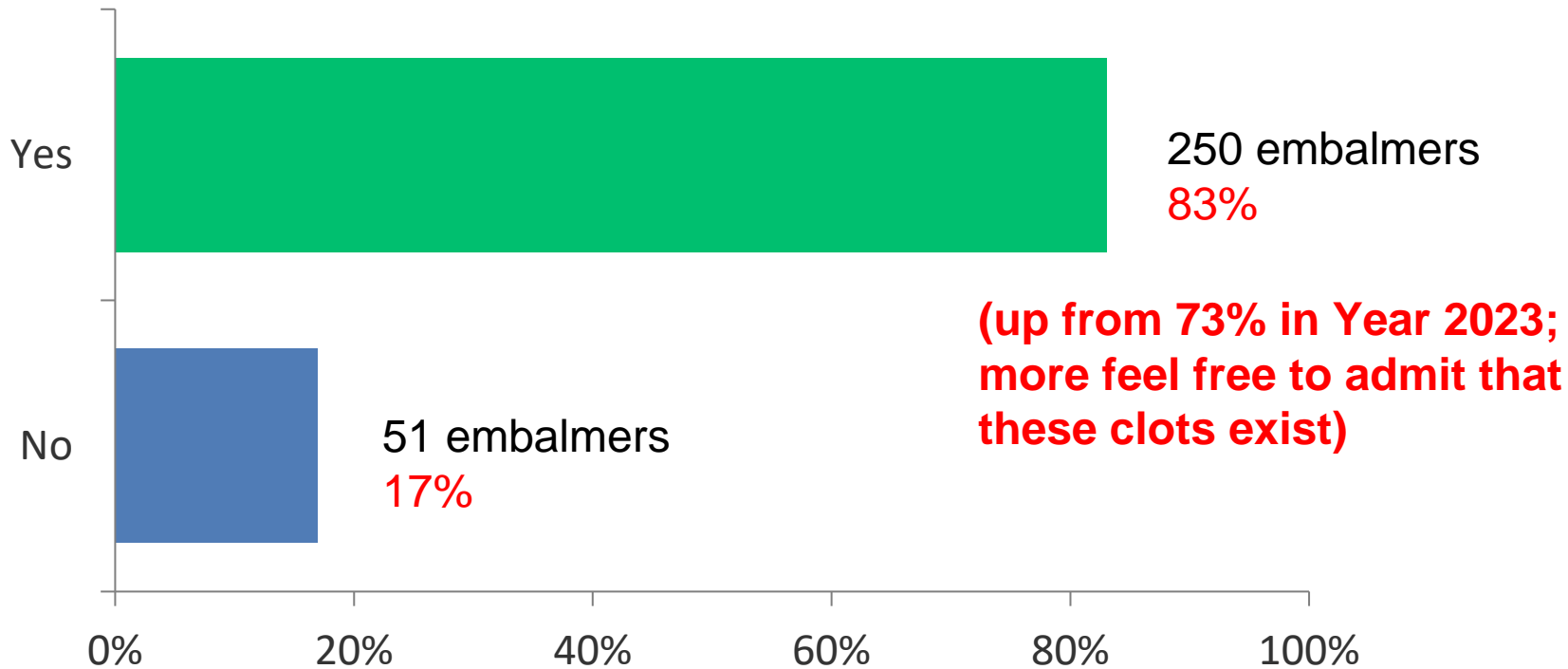
# **2024 WORLDWIDE EMBALMER BLOOD CLOT SURVEY**

**(United States, Canada, United Kingdom, Australia)  
(Conducted 11 Nov – 14 Dec 2024)**

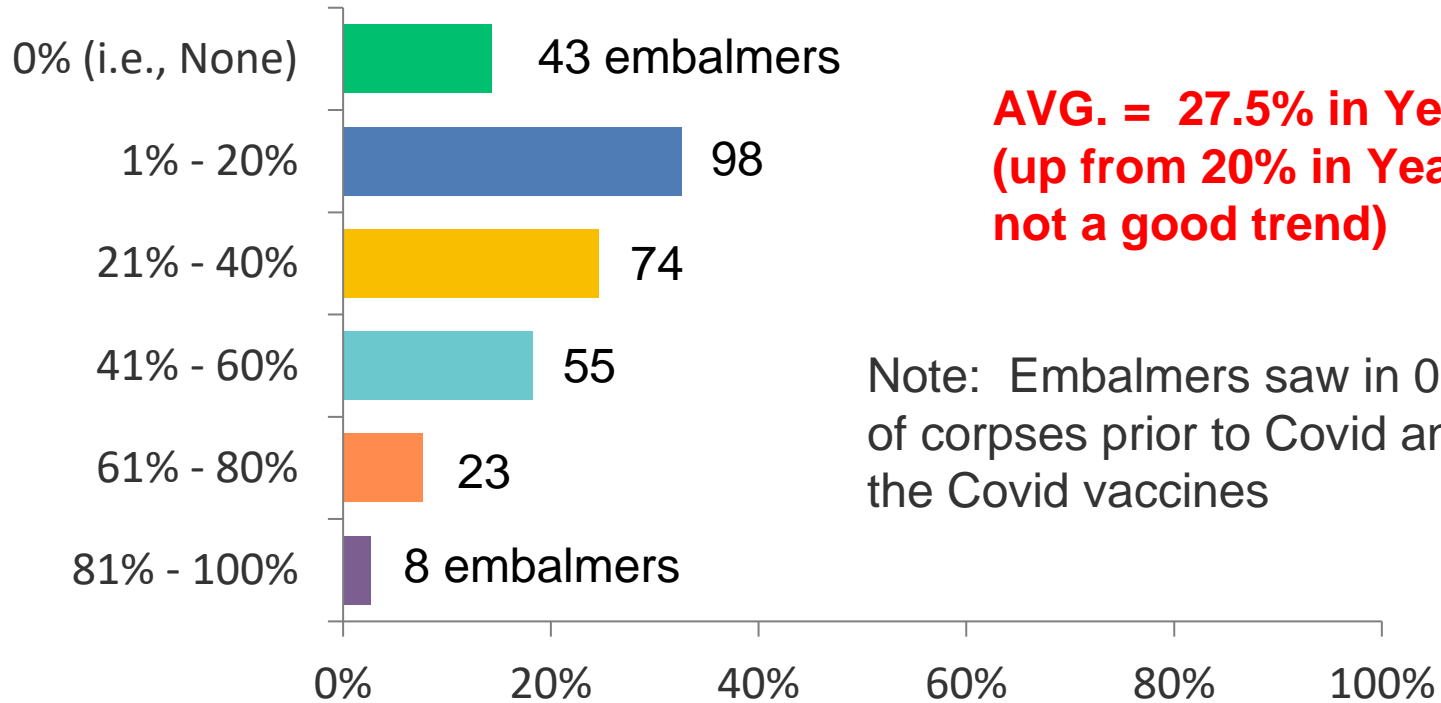
**Thomas F. Haviland  
US Air Force Major, Ret.  
thomashaviland@sbcglobal.net**

## Q2: Did you observe any large whitish "fibrous" structures/clots (as seen in photo above) in the corpses that you embalmed in Year 2024?

Answered: 301 Skipped: 0



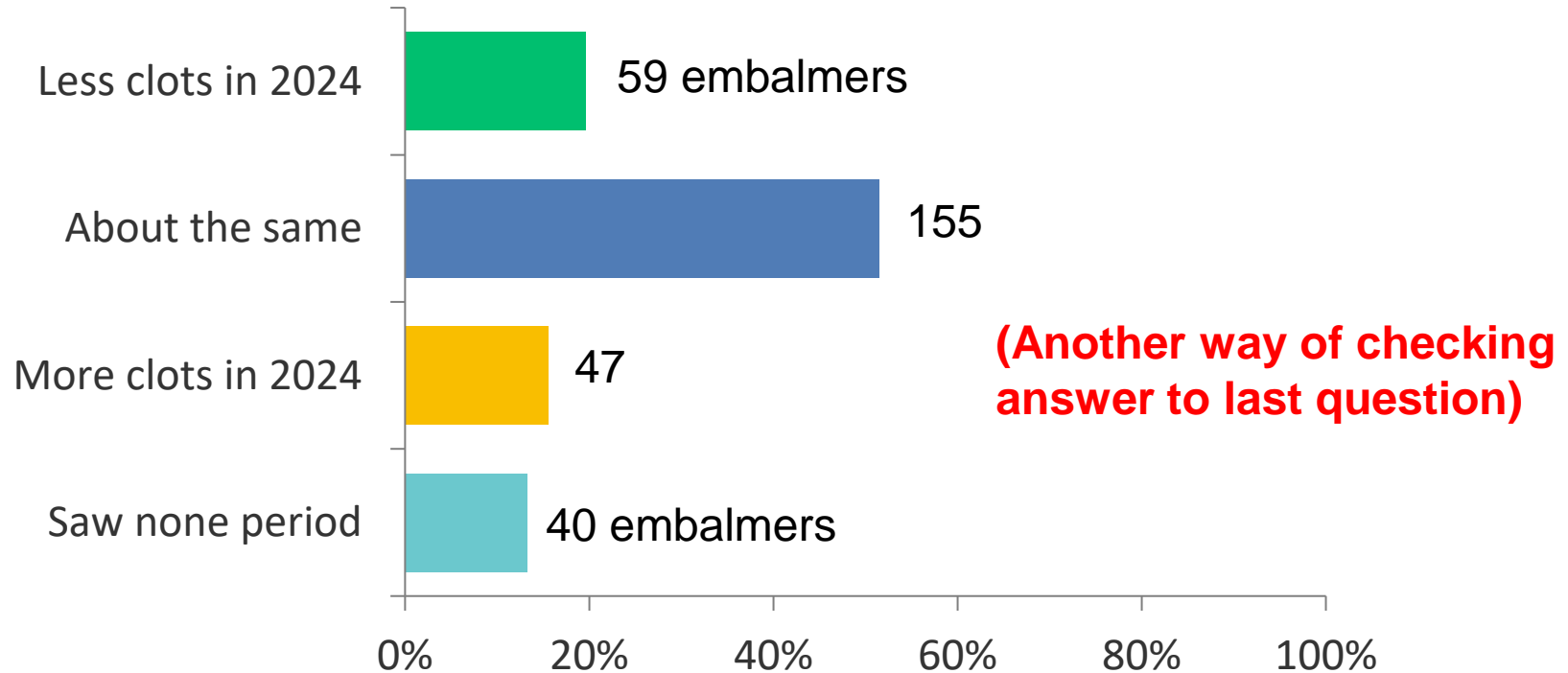
**Q3: What percentage of the corpses in the Year 2024 that you have embalmed have had the large whitish "fibrous" structures/clots? (Please select only one answer.)**



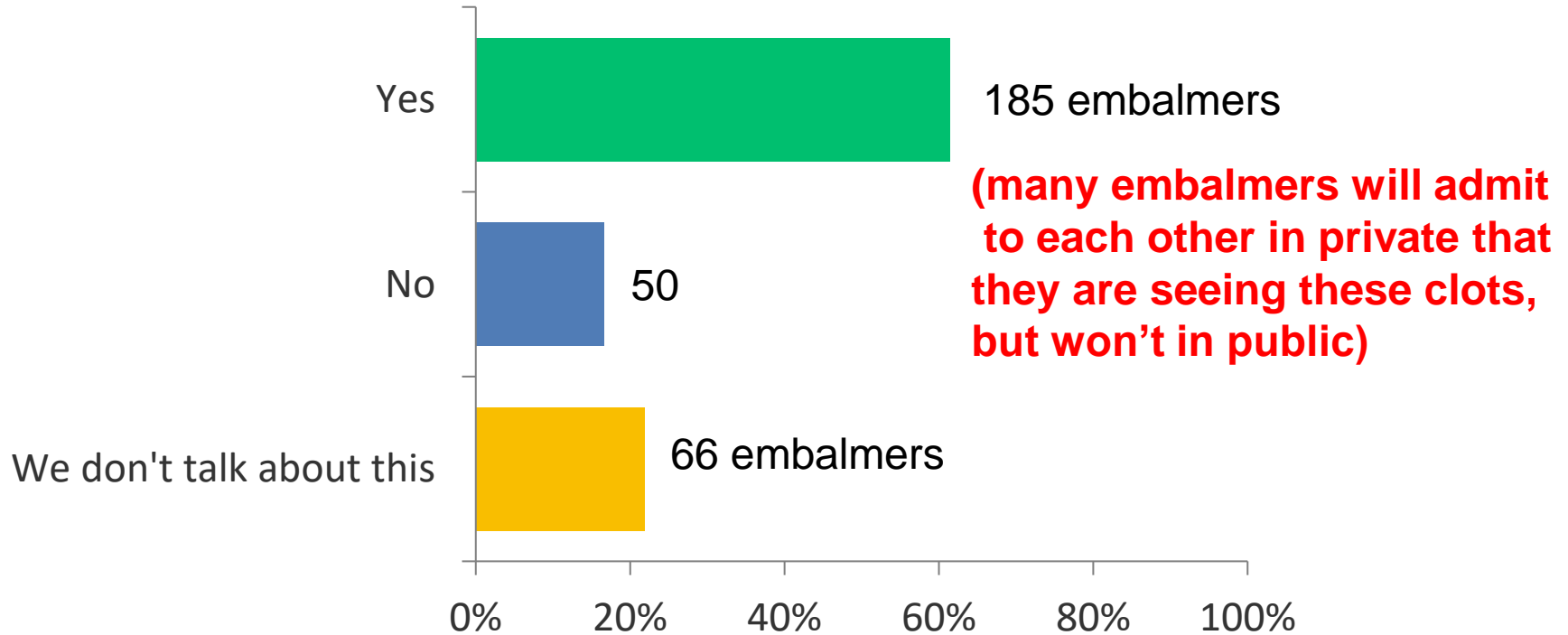
**AVG. = 27.5% in Year 2024  
(up from 20% in Year 2023;  
not a good trend)**

Note: Embalmers saw in 0% of corpses prior to Covid and the Covid vaccines

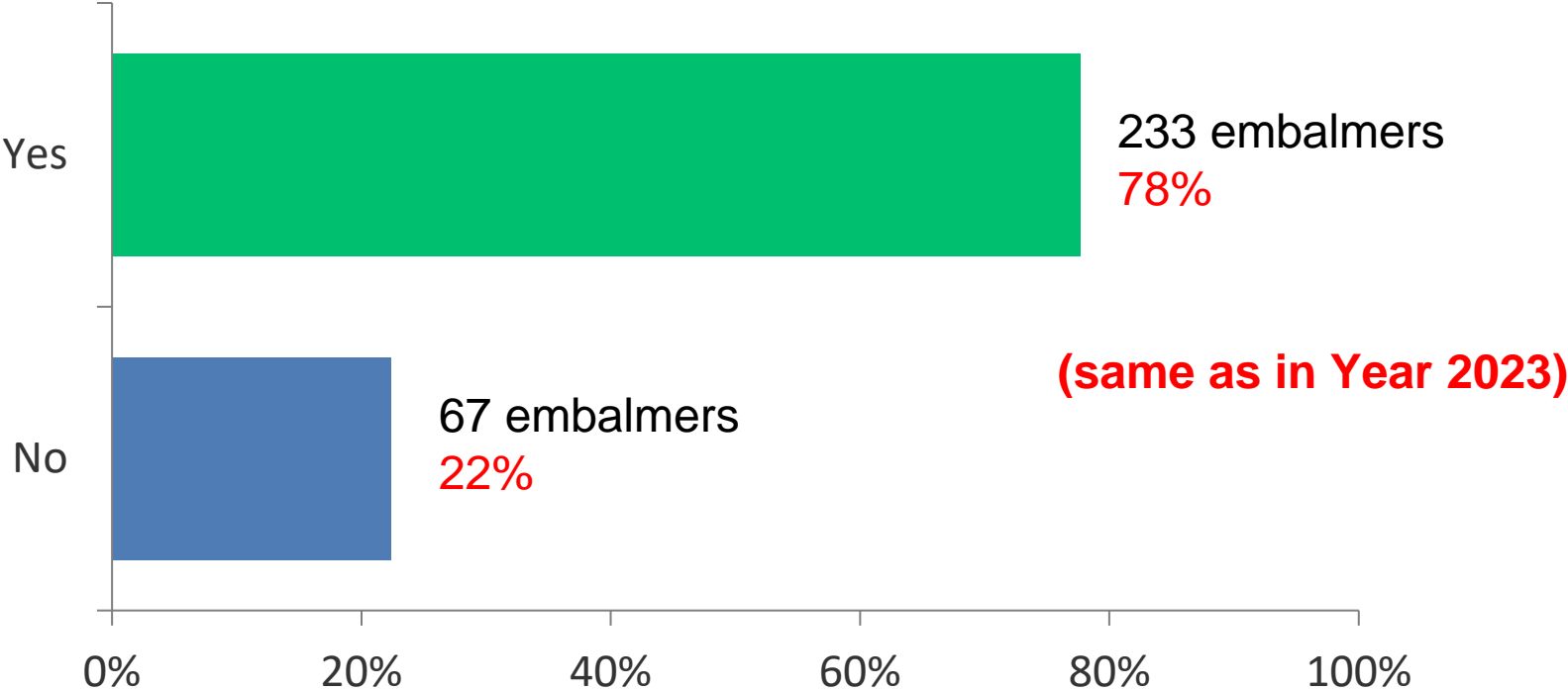
## Q4: Did you see the large whitish "fibrous" structures/clots in a higher percentage of corpses in Year 2024 than in Year 2023?



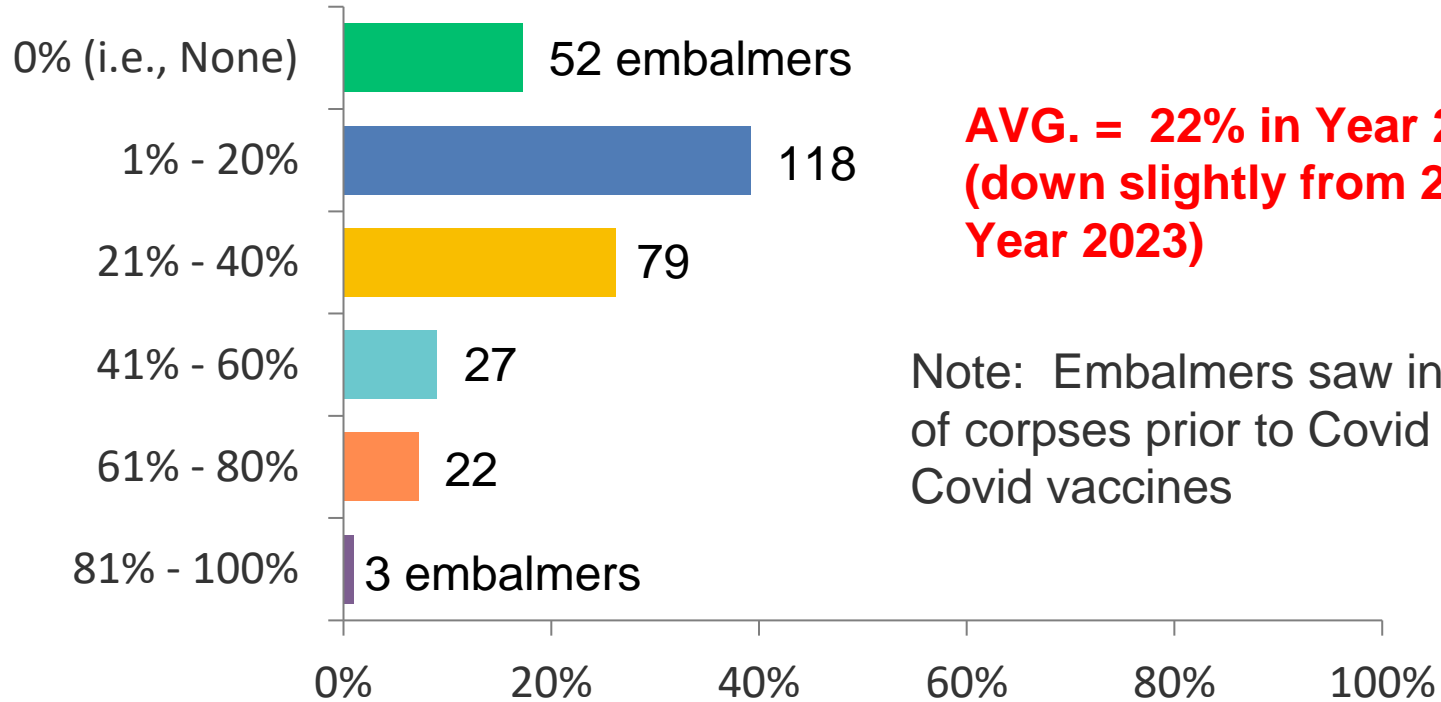
## Q5: Do other embalmers that you talk to say that they are seeing the large whitish "fibrous" structures/clots?



**Q6: Did you observe any "micro-clotting" in the corpses that you embalmed in Year 2024, as evidenced by the appearance of "coffee grounds" or "dirty blood" in the drainage?**



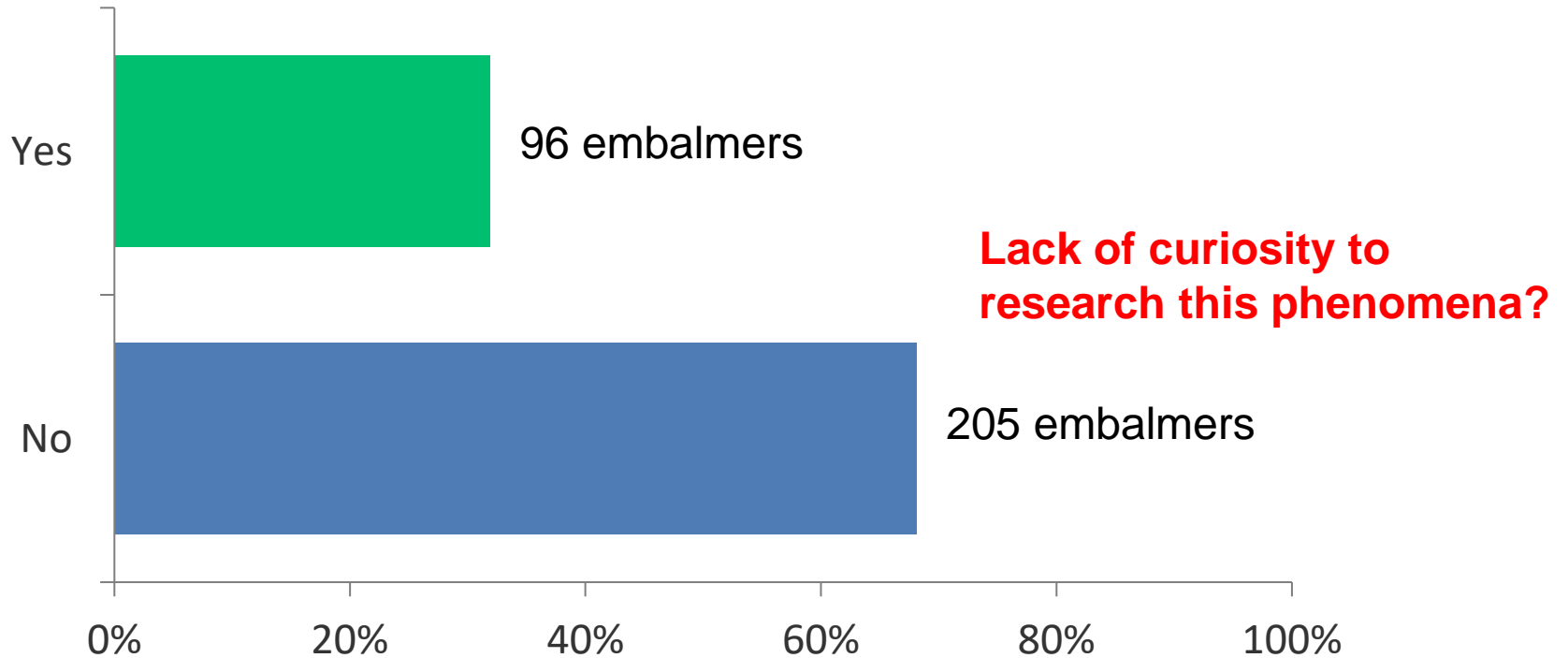
## Q7: What percentage of the corpses in the Year 2024 that you have embalmed have had the micro-clotting/"coffee grounds"/"dirty blood"?



**AVG. = 22% in Year 2024  
(down slightly from 25% in  
Year 2023)**

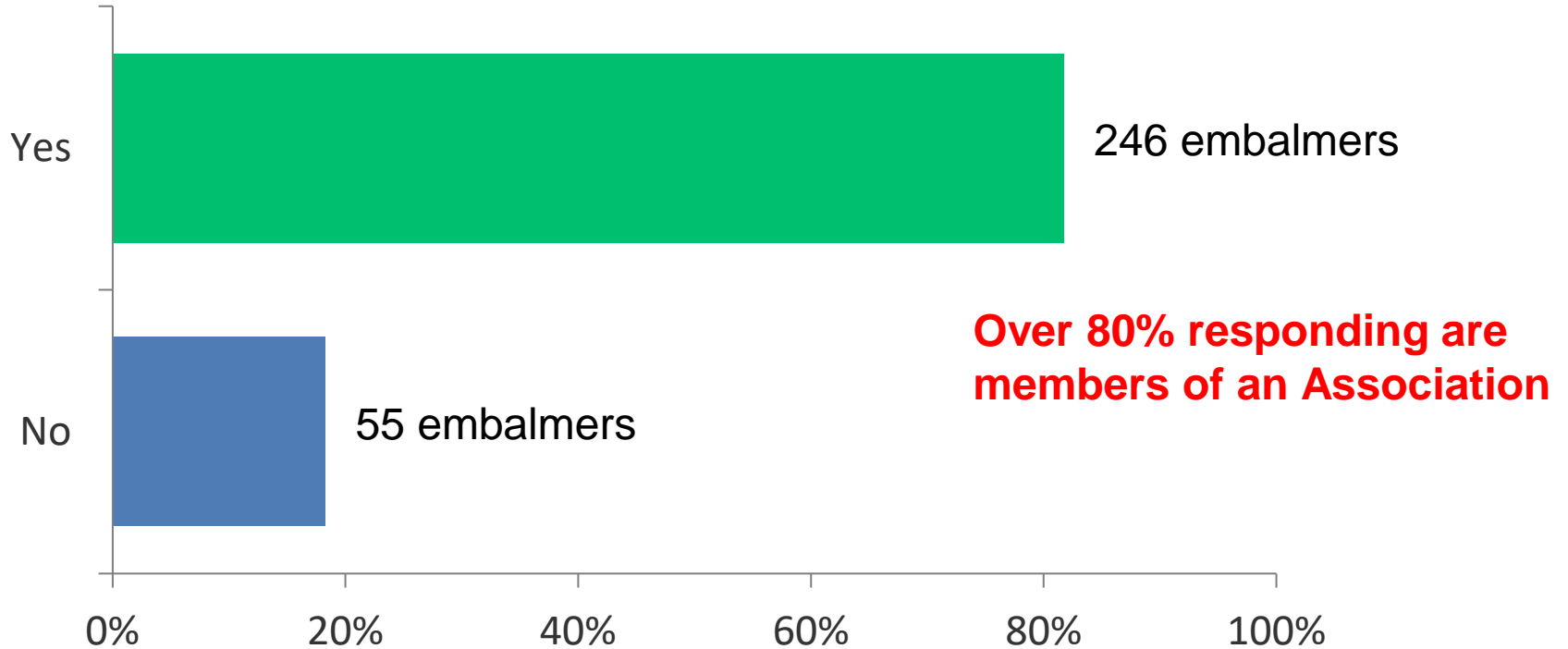
Note: Embalmers saw in <5% of corpses prior to Covid and the Covid vaccines

**Q8: Have you ever watched any online videos (such as "Died Suddenly," YouTube, etc.) or read articles concerning the large whitish "fibrous" structures/clots?**

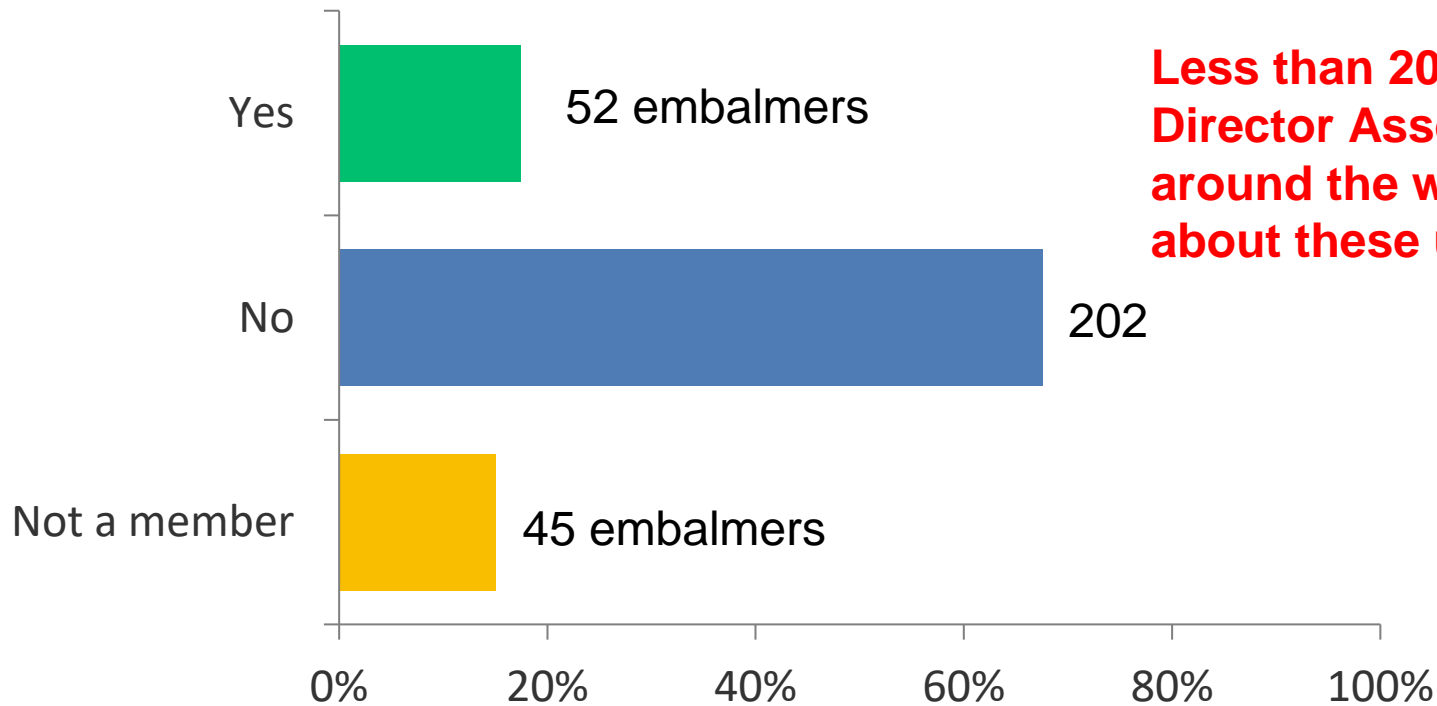




## Q9: Are you a member of a professional embalmer or funeral director association?



# Q10: Has your professional embalmer or funeral director association ever discussed the large whitish "fibrous" structures/clots?



**Less than 20% of Funeral Director Associations around the world are talking about these unusual clots.**

# Embalmers' "Comments"

(a selection from the 80 comments received)

**GEORGIA-** Majority of the cases of decedents I've embalmed who present the large white fibrous clots were in the age range from late 50's to early 70's. Micro-clotting and grape jelly type clotting have been observed almost on every case who have hospitalized prior to death.

**KENTUCKY-** I've been an embalmer since early 2000's for an embalming service I have never seen anything like this before spring of 2021. I have experienced the white fibrous clots that have stretched out to 20". It's like battling a rubber band. My right hand and elbow has suffered from these clots. I've been saying for the last 3 years "this isn't normal" I've recently spoken with a physician that has been hearing this in his field. We are in the same agreement in that we feel we know where this has come from.

**CANADA-** Since the beginning of the COVID-19 pandemic (which I assume this survey is pertaining to) I have not noticed any clots, fibrous structures, or contents in the blood outside of the ordinary. It is also not our responsibility as embalmers to take note of these cases, record or share any information as it is confidential medical information that breaches the privacy clause we have with our client families. Videos and articles such as "Died Suddenly" are anti-vaccine, COVID denying propaganda that is based in no actual fact other than to spread right-wing beliefs and fearmongering the public.

**VIRGINIA-** I'm finding a lot of the white rubbery clots and had been taking pictures of them but it's become the new normal.. I don't use a drain tube anymore because of all the clots. blood clots and the fibrous white ones. My angular forceps is my to go instrument to help remove them..

**NEW YORK-** I've seen the clots vary from case to case, since the covid shot came around, we have had many young\* deaths i.e.: 50-60 year-olds with massive heart attacks and every one of them has had clots as discussed in this survey, seems many people just want to turn a blind eye to it all, it's a shame. As someone who's been around this for about 12 years, I have never seen anything like this.

**OHIO-** The past few years I have seen a significantly larger percentage of clotting in almost all embalmings. These white fibrous clots are definitely unusual having never seen them before 2021. Although not seeing the white fibrous clots or micro clotting in a larger percentage of deceased, the number of grape jelly clots has significantly increased from years past in all decedents.

**IDAHO-** Sometimes I am given the information about if someone has had a certain vaccine. Sometimes I am aware they have had 5-6 doses of it. These are the people we are seeing with the abnormal clots or significant amount of clots.

**FLORIDA-** I have seen both types of blood clots, and definitely seeing the white fibrous clots in larger numbers as time goes. These clots range anywhere from 3 to 6 inches in length with lesser outliers in both directions. Although I do see the grape jelly and coffee they present themselves in a much smaller number. I've been performing approximately a 100 to 150 embalmings per year for the past 4 years. I presently work with 5 other embalming funeral directors who have had much the same experience.

**ARIZONA-** Can't believe we're still talking about this it's a total scam and conspiracy theory Blood clots are caused by refrigeration when bodies are moved in and out repeating or refrigerated for a long duration before embalming.

**FLORIDA-** With many embalmings that I have seen these clots in, I have had to inject in multiple points. Both with case's refrigerated and prep done within a couple of hours after death.

**FLORIDA-** Seems like traditional "chicken fat clots" are less frequent being replaced with Jelly, Fibrous, Micro-clotting.

**IOWA-** Very thick and large, I have had some the whole diameter of the arteries and longer than a foot long.



**LOUISIANA-** Some of these fibrous blots come out as a whole, if done carefully, that mimic the arterial system. These clots are clearly the cause of demise of these decedents, but were legally labeled as heart issues, which are not typically autopsied to fully determine actual cause of death.

**NORTH DAKOTA-** I have had SEVERAL cases in 2020-2023 of the white fibrous clots and most had COVID listed as a factor on their death certificates. However, in each case the family did not know if the decedent was vaccinated.

**FLORIDA-** Unusual clots has changed since COVID vaccine I only took 2 vaccine Pfizer refuse to take booster nor vaccine again